



Contents lists available at ScienceDirect

International Journal of Surgery Case Reports

journal homepage: www.casereports.com

The first case of osteoma of the mandibular notch located both medially and laterally and treated with a transoral endoscopy assisted approach. A case report

Gabriele Bocchialini^{a,*}, Andrea Bolzoni Villaret^b, Stefano Negrini^a, Andrea Tironi^c, Luana Salvagni^d, Andrea Castellani^a

^a Maxillo-Facial Surgery Unit, Asst Spedali Civili – Brescia, Italy

^b Department of Otorhinolaryngology, University of Brescia, Italy

^c Department of Molecular and Translational Medicine, Section of Pathology, University Spedali Civili of Brescia, Brescia, Italy

^d Department of Maxillo-Facial Surgery, University Hospital of Parma, Italy

ARTICLE INFO

Article history:

Received 16 April 2018

Received in revised form 7 May 2018

Accepted 13 June 2018

Available online 26 June 2018

Keywords:

Osteoma

Mandibular notch

Endoscopy

Case report

ABSTRACT

INTRODUCTION: Osteomas are slow-growing benign tumours composed of mature compact or cancellous bone and are seen in facial bones but uncommonly in the mandible; cases that arise in the notch region are rarely reported in the literature.

PRESENTATION OF CASE: This article presents a 37-year-old woman with no preauricular swelling, no limitation of joint motion and pain only on the left side.

DISCUSSION: The patient was evaluated based on preoperative clinical manifestations, orthopantomography and a computed tomography (CT) scan. The CT scan showed bone density irregularity between the coronoid process and the left mandibular condyle in the notch region arising both medially and laterally. Surgery was performed based on these images and the patient's indications and symptoms.

CONCLUSION: Among the cases of osteoma in the literature, only six originated in the mandibular notch, but this is the only that was both medially and laterally located.

© 2018 The Author(s). Published by Elsevier Ltd on behalf of IJS Publishing Group Ltd. This is an open access article under the CC BY-NC-ND license (<http://creativecommons.org/licenses/by-nc-nd/4.0/>).

1. Introduction

Osteomas are uncommon, slow-growing benign tumours composed of mature compact or cancellous bone [1]. They are essentially restricted to the craniofacial skeleton and are rarely, if ever, diagnosed in other bones [2,3]. In the literature, we found only six cases originating in the sigmoid notch of the mandible [4]. The literature describes three different types of osteomas depending on their location [5]: (1) osteomas may arise on the surface of bone as a polypoid or sessile mass (periosteal, peripheral or exophytic osteoma); (2) they may be located in the medullary bone (endosteal or central osteoma); and (3) extra-skeletal soft tissue lesions are typically located within muscle or the dermis of the skin (osteoma cutis).

The aim of this study is to report a case of a particularly rare osteoma that developed in the sigmoid notch region both medially and laterally with particular attention to the histopathological,

radiological, clinical and surgical aspects. This is the first case of an osteoma in the medial and lateral part of the sigmoid notch.

2. Presentation of case

A 37-year-old woman was referred to our institute, with left-sided preauricular pain lasting 1 year and aggravated by palpation, but with no mouth-opening limitation.

She experiences discomfort while chewing food.

There was no history of trauma or other events contributing to onset of the symptoms. A physical examination did not detect any facial nerve paralysis, hearing or facial sensation disturbances. The results of orthopantomography were not significant. A computed tomography (CT) scan with three-dimensional reconstruction revealed bone density irregularity between the coronoid process and the left mandibular condyle with dimensions of 15 × 13 × 11 mm (Figs. 1 and 2). Because the lesion didn't have radiologic features compatible with malignant nature, no exploratory biopsy was performed.

A provisional diagnosis of osteoma was made.

Surgical intervention was performed under general anaesthesia after nasal intubation with a transoral endoscopy assisted

* Corresponding author at: Piazzale Spedali Civili, 1, 23123 Brescia, Italy.
E-mail address: gabriele.bocchialini@libero.it (G. Bocchialini).

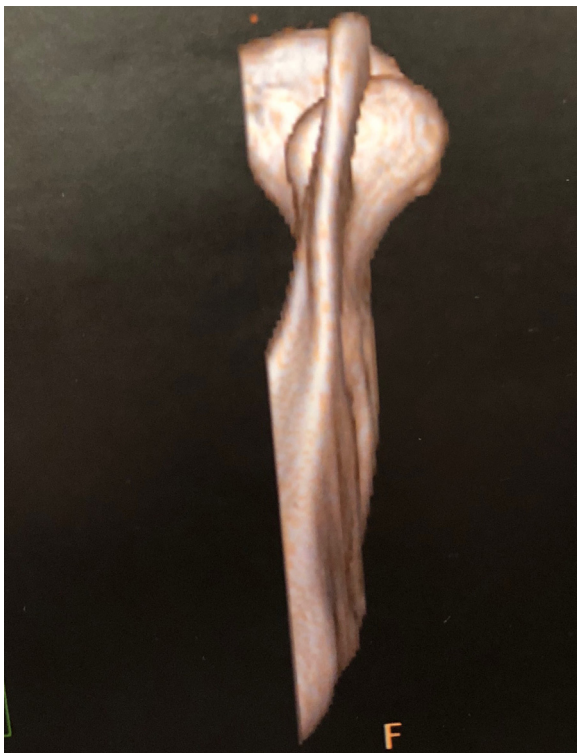


Fig. 1. Preoperative three-dimensional computed tomography scan.

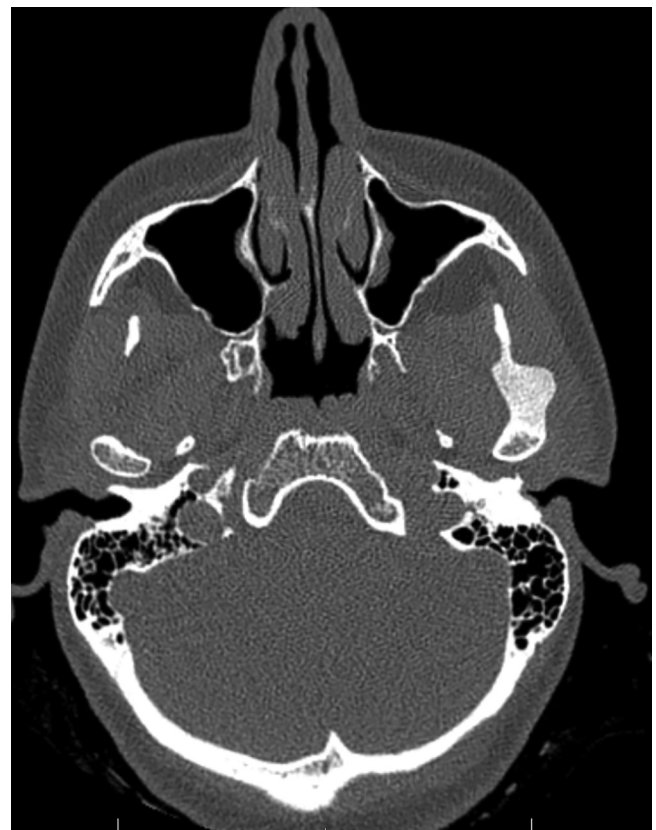

Fig. 3. Intraoperative endoscopic view.

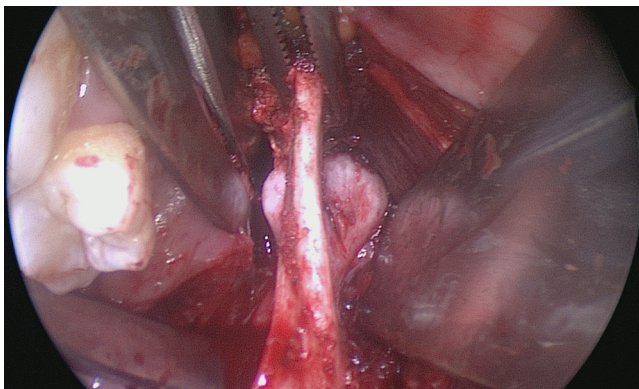


Fig. 2. Axial Ct scan of the Lesion.

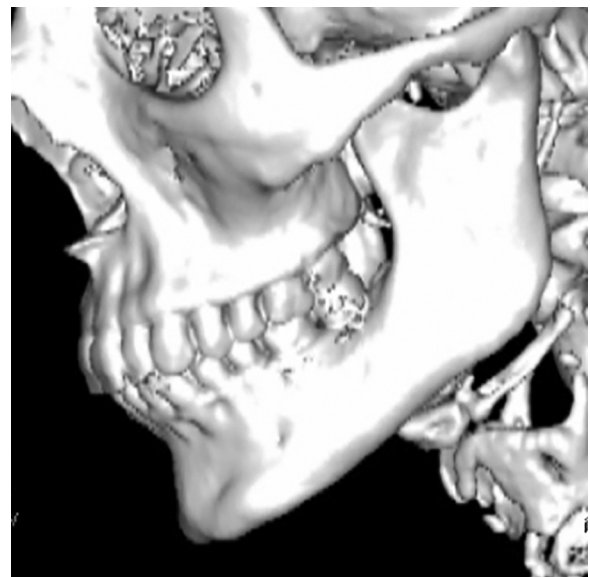


Fig. 4. Postoperative three-dimensional computed tomography scan.

approach. An intraoral anterior ramal incision similar to the one used for a sagittal osteotomy of the mandible was made; the lateral and medial surface of ascending ramus was exposed up to the coronoid process, then the masseter muscle and the temporal tendon were stripped laterally to expose the mass, and the lesion was removed at the level of the sigmoid notch. We visualised the neoformation through an endoscope using 0° and 45° angle optics (Karl Storz, Tuttlingen, Germany) (Fig. 3). Then, we performed an osteotomy of the lesion using a drill with a curved rotary cutter working both medial and lateral to the coronoid process. Coronoidectomy wasn't performed.

The lesion was completely removed and was sent for histopathological evaluation. The surrounding soft tissues were intact. The specimen was a nodular 15 × 13 × 11 mm formation with a hard outer surface.

Primary closure of the wound was achieved with 4-0 Vicryl.

Multiple fragments of mature lamellar bone with few marrow spaces were observed microscopically. These histopathological

findings revealed a diagnosis of compact osteoma. The follow-up period was 12 months without recurrence (Fig. 4).

This case report was written according to the Surgical Case Report guidelines [21].

3. Discussion

Osteoma is defined by World Health Organisation as a benign lesion consisting of well-differentiated mature bone tissue with a predominantly laminar structure and very slow growth [6]; it is

clearly distinct from exostoses and tori, which are hamartomas. Their aetiology remains unknown [7–9].

Some authors have considered that these tumours arise either from embryological cartilaginous nests or from persistent embryological periosteum cells. According to developmental or embryological theory, osteomas would originate from the suture between bones with different embryological derivations (membranous/endochondral) [10]. Other possible aetiological factors are inflammation [11], trauma and endocrine pathologies [12]. However, none of these hypotheses related to the aetiology of these lesions has been proven [13].

We found only six cases in the literature located laterally, medially or in the middle of the sigmoid notch [4]. This case is thus novel because the osteoma was located both medially and laterally.

Osteomas appear radiographically as circumscribed sclerotic masses; periosteal osteomas may have a uniform sclerotic pattern or may demonstrate a sclerotic periphery with a central trabecular pattern [5]. CT is the best imaging modality to determine the location, attachment, extension and anatomical relationship of the lesion [14]. The actual prevalence of osteomas is unknown; however, Sondergard reported that the prevalence of osteoma in the normal population is about 4% [15].

Histological classification is used to differentiate among compact (dense, compact bone), cancellous (soft, spongy bone) and mixed-type osteomas. A compact osteoma consists of mature lamellar bone with few marrow spaces. A cancellous/trabecular osteoma is characterised by bony trabeculae and fibro-fatty marrow enclosing osteoblasts, surrounded by a cortical bone margin. The compact type is the most common type seen in the mandible, as in our case.

The differential diagnosis of osteomas includes exostoses, osteochondroma, osteoid osteoma, periosteal osteoblastoma, parosteal osteosarcoma, peripheral ossifying fibroma, Paget's disease, fibrous dysplasia and odontoma [16,17].

Treatment includes observation with periodic clinical and radiological examinations [18] for small, non-progressing, asymptomatic solitary lesions. Surgery should be considered for large, deforming osteomas [4]. In the present case, excision was considered, as the lesion was progressive and was causing pain during jaw movement.

We adopted an endoscopy assisted transoral approach for aesthetic purposes, which allowed easy access to this unusually located osteoma. The follow-up period is currently 12 months without recurrence. Recurrence of a peripheral osteoma after surgical excision is extremely rare [4]. Malignant transformation of a peripheral osteoma has not been reported in the literature [4].

4. Conclusion

Sigmoid notch osteomas are rare and this is only the seventh such case reported in the English literature [4,12,19,20]. Among the previously reported cases, the mean age at presentation was 48.7 years. In contrast to the other reported cases, our patient's osteoma was located both medially and laterally.

Five cases were females and two were males. The tumour was localised in the right part in four cases and the left in three. Conservative management was adopted in cases where the lesion was asymptomatic (two cases plus one not available); in the present case, pain during mandibular movement and the particular location warranted surgical excision. An osteoma in the mandibular notch region is rare: diagnosis, as well as the description of each new case, is essential for documentation, especially for this type of tumour, which has a very low incidence.

Conflicts of interest

No conflict.

Sources of funding

No found.

Ethical approval

Ethical approval has been exempted by my institution, Spedali Civili Brescia, Italy.

Consent

Written informed consent was obtained from the patient for publication of this case report and accompanying images. A copy of the written consent is available for review by the Editor-in-Chief of this journal on request.

Author contribution

Gabriele Bocchialini have contributed in study concept, data collection, data analysis and interpretation and in writing the paper.

Andrea Bolzoni Villaret have contributed in study concept, data collection and data analysis.

Stefano Negrini have contributed in data collection, data analysis and interpretation.

Andrea Tironi have contributed in data analysis and interpretation.

Luana Salvagni have contributed in study concept and writing the paper.

Andrea Castellani have contributed in study concept, data collection, data analysis and interpretation.

Registration of research studies

No.

Guarantor

Gabriele Bocchialini.

References

- [1] I. Kaplan, S. Calderon, A. Buchner, Peripheral osteoma of the mandible: a study of 10 new cases and analysis of the literature, *J. Oral Maxillofac. Surg.* 52 (5) (1994) 467–470.
- [2] L. Clauser, F. Meneghini, D. Curri, Osteoma of the frontoethmoidal sinuses: craniofacial resection and reconstructive strategy, *J. Craniofac. Surg.* 2 (2) (1991) 75–81.
- [3] J. Gray, R. Snip, Giant, mushroom-shaped osteoma of the orbit originating from the maxillary sinus, *Am. J. Ophthalmol.* 83 (4) (1977) 587–591.
- [4] A. Sasidharan, A. Gohil, S. Koshy, A.K. Gupta, Bony tumour in an unusual location on the mandible, *Indian J. Plast. Surg.* 48 (May–August (2)) (2015) 200–203.
- [5] I. Neville, *Oral and Maxillo-Facial Pathology*, 3rd ed., Elsevier, 2009, pp. 650–651.
- [6] B. Aghabeigi, A.W. Evans, S.J. Crean, C. Hopper, Simultaneous repair of an orbital floor fracture and removal of an ethmoid osteoma: case report and review of the literature, *Int. J. Oral Maxillofac. Surg.* 32 (1) (2003) 94–96.
- [7] I.A. Iatrou, M.D. Leventis, P.E. Dais, K.I. Tosios, Peripheral osteoma of the maxillary alveolar process, *J. Craniofac. Surg.* 18 (5) (2007) 1169–1173.
- [8] K. Kashima, O.I.F. Rahman, S. Sakoda, R. Shiba, Unusual peripheral osteoma of the mandible: report of 2 cases, *J. Oral Maxillofac. Surg.* 58 (8) (2000) 911–913.
- [9] D. Firat, Y. Sirin, B. Bilgic, H. Ozyuvaci, Large central osteoma of the maxillary antrum, *Dentomaxillofac. Radiol.* 34 (5) (2005) 322–325.
- [10] A.P. Varboncoeur, H.J. Vanbelois, L.L. Bowen, Osteoma of the maxillary sinus, *J. Oral Maxillofac. Surg.* 48 (8) (1990) 882–883.
- [11] M. Sugiyama, Y. Suei, T. Takata, C. Simos, Radiopaque mass at the mandibular ramus, *J. Oral Maxillofac. Surg.* 59 (10) (2001) 1211–1214.

- [12] K. Bessho, K.-I. Murakami, T. Iizuka, T. Ono, Osteoma in mandibular condyle, *Int. J. Oral Maxillofac. Surg.* 16 (3) (1987) 372–375.
- [13] J. Regezi, J. Sciubba, *Patologia Bucal. Correlações Clinicopatológicas*, Guanabara Koogan, Rio de Janeiro, Brazil, 1993.
- [14] S. Rao, S. Rao, D.S. Pramod, Transoral removal of peripheral osteoma at sigmoid notch of the mandible, *J. Maxillofac. Oral Surg.* 14 (March (Suppl. 1)) (2015) 255–257.
- [15] J.O. Sondergaard, L.B. Svendsen, J.O. Hegnhoj, N. Witt, Mandibular osteomas in ulcerative colitis, *Scand. J. Gastroenterol.* 21 (1986) 1089–1090.
- [16] A. Greenspan, W. Remagen, Bone-forming tumors, in: A. Greenspan, W. Remagen (Eds.), *Differential Diagnosis of Tumors and Tumor-Like Lesions of Bone and Joints*, Lippincott-Raven Publishers, Philadelphia, Pa, USA, 1998, pp. 25–122.
- [17] A. Cerase, F. Priolo, Skeletal benign bone-forming lesions, *Eur. J. Radiol.* 27 (1) (1998) S91–S97.
- [18] A.E. Sekerci, H. Sahman, E.T. Ertas, Y. Sisman, An unusual peripheral osteoma of the mandibular notch: a case report with computed tomography evaluation, *Oral Radiol.* 27 (2011) 78–82.
- [19] D. Shulze, Radiographic diagnostic: osteoma of the left mandibular notch, *Quintessence Int.* 39 (2008) 702–703.
- [20] T. Iwai, T. Izumi, J. Baba, J. Maegawa, K. Mitsuda, I. Tohnai, Peripheral osteoma of the mandibular notch: report of a case, *Iran. J. Radiol.* 10 (2013) 74–76.
- [21] R.A. Agha, A.J. Fowler, A. Saetta, I. Barai, S. Rajmohan, D.P. Orgill, the SCARE Group, The SCARE statement: consensus-based surgical case report guidelines, *Int. J. Surg.* 34 (2016) 180–186.

Open Access

This article is published Open Access at [sciencedirect.com](https://www.sciencedirect.com). It is distributed under the [IJSCR Supplemental terms and conditions](#), which permits unrestricted non commercial use, distribution, and reproduction in any medium, provided the original authors and source are credited.